



AYURVEDIC MANAGEMENT OF ORAL SUBMUCOUS FIBROSIS- A CASE REPORT

ANJANA S GOKUL^{1*}, GANESH TEJASVI S² AND HARI SANKAR M.S³

- 1: 2nd year M.S. Scholar, Department of Shalaky Tantra, Parul Institute of Ayurved and Research, Parul University, Vadodara, Gujarat, India
- 2: Associate Professor, Department of Shalaky Tantra, Parul Institute of Ayurved and Research, Parul University, Vadodara, Gujarat, India
- 3: Assistant Professor, Department of Swasthavritta, Parul Institute of Ayurved, Parul University, Vadodara, Gujarat, India

*Corresponding Author: Dr. Anjana S Gokul: E Mail: anjanasgokul@gmail.com

Received 25th Feb. 2025; Revised 24th April 2025; Accepted 16th June 2025; Available online 1st May 2026

<https://doi.org/10.31032/IJBPAS/2026/15.5.10079>

ABSTRACT

Background: Oral hygiene plays a vital role in maintaining overall health but can be compromised by habits like betel nut chewing. Betel nut consumption is a primary cause of Oral Submucous Fibrosis (OSMF), a progressive disorder marked by chronic inflammation and fibrosis of the oral mucosa. The condition develops gradually, leading to restricted mouth opening (trismus), burning sensations, difficulty in eating, and, in severe cases, difficulty swallowing (dysphagia). In Ayurveda, OSMF shares similarities with *Sarvasara Mukhapaka*, which occurs due to the imbalance of *tridoshas* (*Vata*, *Pitta*, and *Kapha*).

Objective: This study aims to explore the efficacy of Ayurvedic therapies in managing OSMF, emphasizing the role of localized treatments such as *Pratisarana* (therapeutic rubbing) and *Kavala* (oil pulling) as part of a comprehensive treatment approach. **Methods:** A single patient diagnosed with OSMF was treated using Ayurvedic interventions designed to alleviate symptoms and address the root causes. The treatment protocol included *Pratisarana* and *Kavala* to reduce fibrosis and inflammation. Systemic medications and lifestyle modifications, including cessation of betel nut consumption, were also prescribed to enhance therapeutic benefits. **Results:** Significant improvement was observed in the patient, including increased interincisal

distance and reduced symptoms such as burning sensation and eating difficulty. The treatments not only provided symptom relief but also contributed to reversing the pathological changes characteristic of OSMF.

Conclusion: This case highlights the effectiveness of Ayurvedic treatments in managing OSMF. Localized therapies like *Pratisarana* and *Kavala* demonstrated anti-inflammatory, wound-healing, and fibrosis-reducing properties, resulting in improved patient outcomes. Further research is recommended to validate these findings and establish Ayurveda as a complementary approach to OSMF management.

Keywords: Oral submucous fibrosis, Kavala, Pratisarana, Mukhapaka

INTRODUCTION

Oral submucous fibrosis (OSMF) is a precancerous condition characterized by inflammation and progressive thickening of the submucosal tissues, resulting in stiffness and restricted mouth opening (trismus). In India, betel nut chewing is a primary risk factor associated with the development of OSMF. Arecoline from betel nuts and copper are key components of betel quid that contributes to fibroblast dysfunction and the formation of fibrotic bands. OSMF is characterized by fibrosis in the submucosal layer, affecting much of the oral cavity. This leads to severe lockjaw caused by stiffness in lips, cheeks, pharynx, and the upper third of the esophageal canal, eventually progressing to difficulty in swallowing (dysphagia). The prevalence of OSMF is rising, particularly among younger generations, as more commercially available areca nut products like gutka (chewing tobacco) and others are being introduced [1].

The precise cause of OSMF remains unclear, but it is considered to be multifactorial.

Tobacco and areca nut (Areca catechu) consumption are recognized as significant contributing factors. Areca nut contains compounds such as tannins, arecoline, arecaidine, guvacine, and guvacoline, which play a major role in its development [2]. The majority of OSMF cases are observed in the Indian population. Despite extensive research over years, particularly in South Asia, OSMF remains poorly recognized and inadequately understood worldwide. Its incidence is increasing, with limited advancements in management and no substantial reduction in its high rate of malignant transformation [3]. According to Ayurveda, OSMF can be understood as *Sarvasara mukharoga* which includes *Vataja*, *Pittaja*, *Kaphaja*, *Raktaja* and *Sannipataja mukhapaka* all of which are *Sadhya rogas*. On analyzing the disease condition some scattered references are seen in *mukharoga* and *vraha* related chapters. Few symptoms like inability to open mouth (*Kruchhen Vivrunoti-Vataja Sarvasara*) [4], burning sensation in mouth (*Daha- Pittaja*

Sarvasara) [5, 6] pain in mouth (*Toda-Vatika Sarvasara*), intolerance to spicy food (*tikshnasaha*) [7], ulceration of oral mucosa (*Mukhantargatha vrana*) [8] etc. are found in *Mukharoga*. The *Samprapti* (pathogenesis) of Oral Submucous Fibrosis (OSMF) involves the imbalance of specific *doshas*, particularly *Vyana Vata*, *Prana Vata*, and *Udana Vata*, alongside *Bodhaka Kapha* and *Bhrajaka Pitta*. *Vyana Vata* governs the abnormal distribution of nutrients, leading to fibrosis and restricted mouth opening, while *Prana Vata* and *Udana Vata* contribute to impaired swallowing and speech. *Bodhaka Kapha* is disrupted, affecting saliva secretion and leading to dryness and intolerance to spicy foods. Additionally, the aggravation of *Bhrajaka Pitta* impacts the skin and mucosal layers, causing burning sensations and inflammation. Together, these imbalances drive the progression of OSMF. Thus, OSMF can be considered as the *Vata- Pitta Pradhana Tridoshaja Mukharoga*.

Mukharogas commonly use external application, gargling and retaining oil or decoction in the oral cavity as local remedies for disease of the oral cavity. OSMF is treated with a variety of single and combination medicines. Efficacy of *kavala* and *pratisarana* along with *khadiradi vati* chewing have been studied in this case study.

CASE DESCRIPTION

PATIENT INFORMATION

A 65 year old male patient came to the outpatient department of Shalaky Tantra, Khemdas Hospital, Parul university, Vadodara with symptoms of difficulty in opening of mouth, intolerance towards spicy food and burning sensation, reduced food consumption since 3 months, aggravated since 15 days. On other investigations no other systemic illness was present.

ASHTASTHANA PARIKSHA (EIGHT-FOLD EXAMINATION)

Naadi (pulse)- Vata

Mootra (micturition)- Samanya(normal)

Mala (defecation)- Prakritha (normal)

Jihwa (tongue)- Liptha (coated)

Shabda (voice)- Prakritha (normal)

Sparsha (touch)-Anushnasheeta (normal)

Drik (vision)- Samanya (normal)

Aakrithi (body structure)- Durbala (weak)

DASHAVIDHA PARIKSHA (TEN- FOLD EXAMINATION)

Prakriti (constitution)-Vata pitta

Vikriti (Pathology)- Tridosha

Sara (Quality of tissue)- Avara (reduced)

Samhanana (structural integrity)- Madhyama (normal)

Satwa (mental status)- Madhyama (normal)

Satmya (adaptability)- Madhyama (normal)

Pramana (measurement)- Height:162cm
Weight:50 kg

Ahara shakthi (digestive capacity)-

Abhyavaran shakthi- Avara (reduced)

Jarana shakthi- Madhyama (normal)

Vyayama shakthi(exercise tolerance capacity)- Madhyama (normal)

Vaya (stage of life)- Vruddha (oldage)

CLINICAL FINDINGS

On examination-

Black pigmentation of dentition, with dental caries and gingival recession.

Submucous fibrosis present in retromolar trigone

5-6 patches of ulcers were seen which were reddish white in colour.

On first day, Inter-incisal distance as measured in Vernier caliper was- 4.8 mm

History of tobacco consumption x 10 years

TIMELINE

TIMELINE – Fig 1

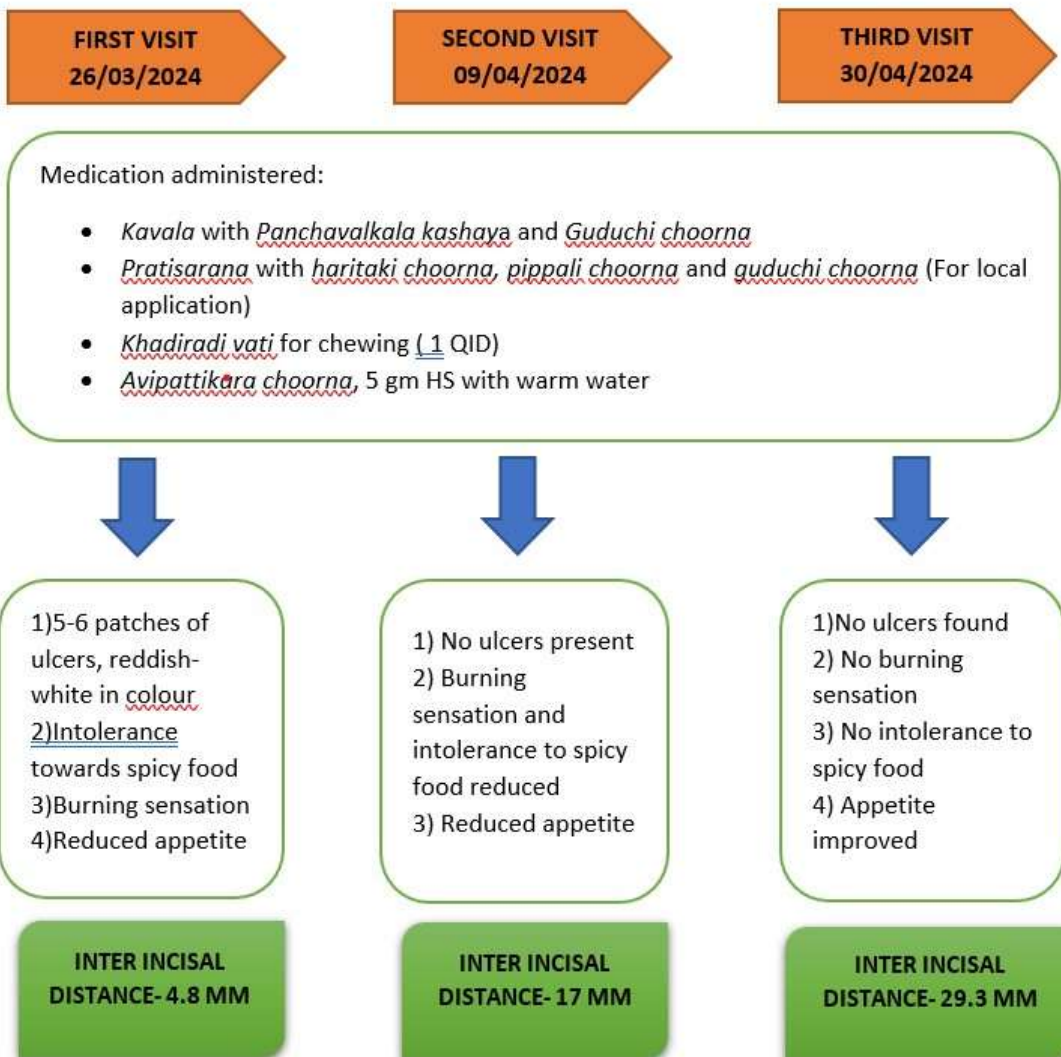


Figure 1: Timeline

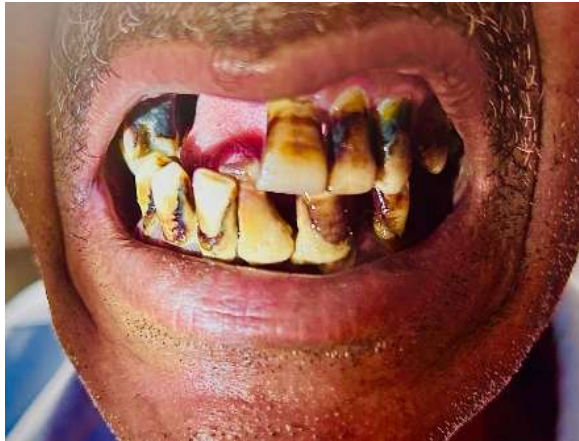

Figure 2: Before treatment-Inter incisal distance-4.8mm

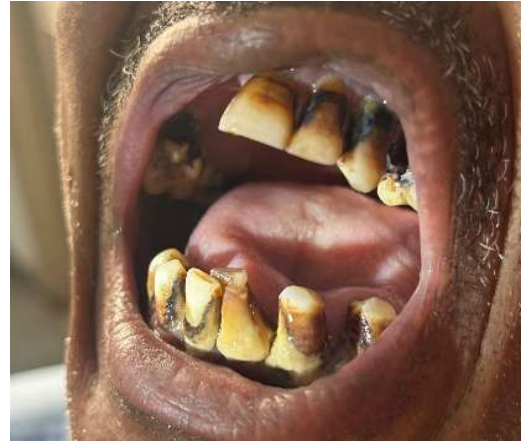

Figure 3: After treatment- Interincisal distance-29.3mm

DIAGNOSTIC ASSESSMENT

Oral Submucous Fibrosis (OSMF) was diagnosed based on clinical evaluation, including reduced interincisal distance and the presence of oral ulcers. No other systemic conditions were present.

THERAPEUTIC INTERVENTION

1. The patient was advised to do *Pratisarana* with *Haritaki choorna* (30gm), *Pippali choorna*(20gm) and *Tankana bhasma* (5gm) for 30 days.
2. Kavala was advised to be done with *panchavalkala kashaya* and *guduchi choorna*.
3. Internally *Khadiradi vati* was given for chewing

Patient was asked to discontinue all existing habits and consumption of a normal diet was advised. Tablets to be taken orally after food after consuming the medication. Patient was

advised not to eat, drink or gargle for about an hour, to prevent dilution of the medication.

FOLLOW UP AND OUTCOMES

The patient was assessed during two follow-up visits at two-week intervals. By the first follow-up, the burning sensation had significantly decreased, and the mouth-opening capacity improved to 17.2 mm, with better tolerance to spicy foods. During the second follow-up, the mouth-opening further increased to 29.3 mm, with complete relief from burning sensation, oral discomfort, and food intolerance. Improvements were also observed in oral hygiene, reduction in fibrosis, and enhanced flexibility of the oral tissues. The treatment was well-tolerated, with no adverse effects, confirming the safety and therapeutic effectiveness of the Ayurvedic interventions. Lifestyle changes such as cessation of tobacco chewing, avoiding spicy

food and alcohol, adopting a soft diet and hydration were also advised.

DISCUSSION AND CONCLUSION

Oral submucous fibrosis (OSMF) is a collagen metabolic disorder primarily linked to the chewing of areca nut, with or without tobacco. Globally, the condition is most prevalent in Southeast Asia and India, with an estimated prevalence ranging from 0.2% to 0.5% [9]. Recognized as a potentially malignant disorder, OSMF poses a significant risk of transformation into malignancy [10]. The pathogenesis of OSMF is largely driven by chronic inflammation associated with areca nut chewing, which stimulates fibroblasts and leads to the activation of various cytokines. These factors influence genes and proteins involved in collagen metabolism, ultimately resulting in decreased collagen degradation and increased collagen production, thereby contributing to the development of fibrosis. Areca nut and its compounds also impact epithelial cells, promoting conditions that may lead to neoplastic changes. Despite advancements in treatment options, there is currently no definitive cure for OSMF, and the risk of malignant transformation remains unchanged. This underscores the need for therapeutic strategies that not only manage the condition but also prevent its progression to malignancy.

Pratisarana and *kavala* are the local therapies mostly used in *mukharogas*. Here local therapy is to prevent and reverse the fibrosis. The *pratisarana yoga* used here has overall *lekhana*, *shothahara*, *vranashodhaka*, *vranaropaka vata pitta* dominant *tridosha shamaka* action as well as most of the drugs possess antioxidant and anti-inflammatory action. It has more tissue contact time and it is used for healing and reverse the clinical picture of OSMF.

Haritaki portrays strong anti-bacterial, anti-viral and anti-fungal properties that are not only used for removing bacteria and germs from the body but also treats wounds and improved healing. *Tankana* acts as a *kshara* thus acting on ulcers. *Tankana* carries properties like *kapha vishelshaka* and *vatahara* due to *katu rasa, ushna virya* and *tikshna guna*. *Katu rasa* and *tikshna guna* helps the drugs to penetrate the deeper parts of oral mucosa. *Katu rasa* along with *ruksha, tikshna guna* acts as *lekhana* and *marga vishodhana*, which helps in reduction of *ragata* and *shotha* [11, 12]. In vitro antimicrobial study of *tankana* reveals that it was effective against bacterial strains *E coli*, *p.aeruginosa*, *S.aureus*, *S.pyogenes* and fungal strains *C.albicans*, *A.niger* and *A. clavatus* [13]. *Pippali Choorna* is highly effective in treating *Mukhavrana* (mouth

ulcers). It reduces inflammation and alleviates pain through its anti-inflammatory and analgesic properties. Its antimicrobial effects prevent secondary infections, while its immunomodulatory action enhances the body's natural healing response. It also improves digestion, aiding in nutrient absorption and toxin elimination, which can contribute to ulcer formation. Additionally, it balances *Vata* and *Kapha doshas*, addressing the root causes of mouth ulcers. Its astringent properties help contract tissues and protect the ulcerated area, promoting faster healing and overall oral health [14, 15].

Kavala strengthens oral mucosa and hence promotes easy penetration of the drug. It is useful as physiotherapeutic measure [16]. *Panchavalkala Kwatha*, made from the barks of five *Ficus* species (*Ashvattha*, *Vata*, *Plaksha*, *Udumbara*, and *Parisha*), offers significant therapeutic benefits for managing oral ulcers (*Mukhavrana*). Its cooling (*Sheetha Virya*) and blood-purifying (*Rakta Shodhaka*) properties help soothe burning sensations and detoxify the oral cavity, promoting ulcer healing by eliminating toxins [17]. The decoction's wound-healing (*Vranapaha*) and *Tridosahara* effects are crucial in treating ulcers, which often result from imbalances in *Vata* and *Pitta doshas*. *Guduchi* has anti-inflammatory, antioxidant

property and exert immunostimulatory effects [18, 19]. Various in vitro studies suggest that *guduchi* also has antifibrotic action [20].

The chief ingredient of *Khadiradi vati* is *Acacia catechu*, an excellent antimicrobial and anti-inflammatory agent. It increases intracellular concentration of Vitamin C, free radical scavenging, and inhibition of collagen destruction [21].

In this case of OSMF, the Ayurvedic treatment significantly increased the interincisal distance, effectively reducing trismus (**Figure 1 and 2**). *Pratisarana* and *Kavala* therapies, with their *lekhana*, *shothahara*, and *vranaropaka* properties, reversed fibrosis and promoted healing. *Kavala* with its physiotherapeutic action, strengthened the oral mucosa and enhanced drug penetration. Ingredients like *Haritaki*, *Tankana*, and *Pippali choorna* contributed antimicrobial, anti-inflammatory, and wound healing effects. *Panchavalkala Kashaya* and *Guduchi* supported healing through their antifibrotic and immunomodulatory actions, while *Khadiradi vati* prevented collagen destruction. This holistic approach successfully alleviated symptoms, reduced fibrosis and improved oral function.

CLINICAL SIGNIFICANCE

This case study underscores the effectiveness of Ayurvedic treatment in managing Oral

Submucous Fibrosis, a condition known for its progressive nature and risk of malignant transformation. Conventional treatments are not having definitive cure, necessitating alternative therapeutic approaches. This study demonstrates how Ayurvedic interventions contribute to reducing the symptoms and enhancing the mouth opening capacity, thereby improving the patients overall quality of life. The findings highlight the potential of Ayurveda in integrative oral healthcare and encourage further research into its role in managing OSMF safely and effectively.

PATIENT PERSPECTIVE

The patient expressed gratitude for the holistic Ayurvedic treatment they received, highlighting the significant improvement in their condition and overall well-being. They appreciated the comprehensive and personalized approach taken by the healthcare team, which focused on addressing both the physical symptoms and improving their quality of life. The patient reported feeling more confident and comfortable in daily activities and acknowledged the positive impact of the treatment on their overall health. They were particularly thankful for the consistent guidance and support provided throughout the course of their care, which contributed to their substantial recovery within a short period.

INFORMED CONSENT

The authors confirm that all necessary patient consent forms have been obtained. In these forms, the patient has provided consent for their image and clinical information to be published in the journal. The patient understands that their name and initial will not be disclosed, and every effort will be made to protect the identity; yet total anonymity cannot be assured.

CONFLICT OF INTEREST- Nil

ACKNOWLEDGEMENT- Nil

REFERENCES

- [1] Chhabra AK, Sune R, Reche A. Oral submucous fibrosis: a review of the current concepts in management. *Cureus*. 2023 Oct 18;15(10):e47259. doi:10.7759/cureus.47259. PMID: 38022118; PMCID: PMC10655494
- [2] Shivapathasundharam B. Shafer's Textbook of Oral Pathology. 8th ed. Amsterdam, Netherlands: Elsevier, Inc.; 2016. p. 149.
- [3] Rao NR, Villa A, More CB, et al. Oral submucous fibrosis: a contemporary narrative review with a proposed inter-professional approach for an early diagnosis and clinical management. *J Otolaryngol Head Neck Surg*. 2020;49(3). doi:10.1186/s40463-020-0399.

- [4] Murthy KRS, Vagbhata's Ashtanga Hridayam, Uttaratantra, Ch.21, Ver.59. 10th ed (Reprint) Varanasi: Chuakambha Krishnadas Academy; 2018, p.195
- [5] Acharya YT, editor. *Sushruta Samhita of Sushruta, Nidanasthana, Ch. 16, Ver. 65*. 3rd ed. Varanasi: Chaukhambha Surbharati Prakashana; 2014. p. 336.
- [6] Murthy KRS, Vagbhata's Ashtanga Hridayam, Uttaratantra, Ch.21, Ver.60. 10th ed (Reprint) Varanasi: Chuakambha Krishnadas Academy; 2018, p.196
- [7] Murthy KRS, Vagbhata's Ashtanga Hridayam, Uttaratantra, Ch.21, Ver.5. 10th ed (Reprint) Varanasi: Chuakambha Krishnadas Academy; 2018, p.185
- [8] Acharya YT, editor. *Sushruta Samhita of Sushruta, Nidanasthana, Ch. 16, Ver. 65-6*. 3rd ed. Varanasi: Chaukhambha Surbharati Prakashana; 2014. p. 336
- [9] Sudarshan R., Annigeri R.G., Vijayabala S.S. Aloe vera in the treatment for oral submucous fibrosis—A preliminary study. *J. Oral Pathol. Med.* 2012;41:755–761. doi: 10.1111/j.1600-0714.2012.01168.x.
- [10] Warnakulasuriya S., Johnson N.W., Van Der Waal I. Nomenclature and classification of potentially malignant disorders of the oral mucosa. *J. Oral Pathol. Med.* 2007;36:575–580. doi: 10.1111/j.1600-0714.2007.00582.x.
- [11] Sadhana P, Amulya D, Pramod B. *Rasa Ratna Samuccaya*, Chapter 10, Verses 45–50. 2021.
- [12] Parajuli S, Dahal A, Bhatta P. Effectiveness of Tankana Bhasma Kavala in Tonsillitis. *J Ayurveda IntegrMedSci.*2019;6(1):80–3. doi:10.21760/jaims.v6i01. <https://doi.org/10.21760/jaims.v6i01.1184>
- [13] Kumar et al., In vitro anti inflammatory activity of Tankana churna, *Food and Feed Research* 40 (1), 17-20, 2013
- [14] Biswas P, Ghorai M, Mishra T, Gopalakrishnan A, Roy D, Mane A, et al. Piper longum L.: A comprehensive review on traditional uses, phytochemistry, pharmacology, and health-promoting activities. *Phytother Res.* 2022;36. doi: 10.1002/ptr.7649.
- [15] Subramaniam K, Subramanian S, Bhargava S, Parameswari R, Praveena R, Ravikumar R, et al. Review on potential antiviral and immunomodulatory properties of Piper longum. *IOP Conf Ser Mater Sci Eng.* 2021;1145:012099. doi: 10.1088/1757-899X/1145/1/012099.
- [16] Naseem M, Khiyani MF, Nauman H, Zafar MS, Shah AH, Khalil HS. *Oil*

- pulling and importance of traditional medicine in oral health maintenance. *Int J Health Sci (Qassim)*. 2017 Sep-Oct;11(4):65-70. PMID: 29085271; PMCID: PMC5654187.
- [17] B. Tripathi, *Charaka Samhita, Part-II*, reprint ed. Chaukhambha Subharati Prakashan, Varanasi.: 2013, Ch. 25, verse-67, pp. 851.
- [18] Sharma U, Bala M, Kumar N, Singh B, Munshi RK, Bhalerao S. Immunomodulatory active compounds from *Tinospora cordifolia*. *J Ethnopharmacol*. 2012 Jun 14;141(3):918-26. doi: 10.1016/j.jep.2012.03.027. Epub 2012 Mar 26. PMID: 22472109.
- [19] S, Rana J, Sehgal AK, Sagar A., Antimicrobial Activity, Antioxidant Potential and Phytochemical Constituents of *Tinospora cordifolia* (Giloya): A Review. *AAM*. (2024), [cited November 14, 2024]; 13(4): 287-300. doi:10.5455/AAM.157727
- [20] Patil S. Potential Application of an Aqueous Extract of *Tinospora Cordifolia* (Thunb.) Miers (Giloy) in Oral Submucous Fibrosis-An In Vitro Study. *Materials (Basel)*. 2021 Jun 18;14(12):3374. doi: 10.3390/ma14123374. PMID: 34207082; PMCID: PMC8234184.
- [21] Sinha N, Pal K, Parashar P, Agrawal SK, Bhatt U. A clinical study using *A. catechu*, menthol, and camphor powder on oral health. *Natl J Maxillofac Surg*. 2018;9:71–6. doi: 10.4103/njms.njms_65_17